

# Port-wine stain and glaucoma in a 29-year-old male

Karen Kate Quilat,<sup>1</sup> Eshir A Ismael<sup>1,2</sup>

<sup>1</sup>Department of Ophthalmology,  
Southern Philippines Medical Center,  
JP Laurel Ave, Davao City, Philippines

<sup>2</sup>Maguindanao Provincial Hospital,  
Shariff Aguak, Maguindanao,  
Philippines

## Correspondence

Karen Kate Quilat  
kitkat.bq@yahoo.com

## Article editor

Billie Jean Cordero

## Received

2 June 2017

## Accepted

10 November 2017

## Published online

16 November 2017

## Cite as

Quilat KK, Ismael EA. Port-wine  
stain and glaucoma in a 29-year-old  
male. *SPMC J Health Care Serv.*  
2017;3(2):1.  
<http://n2t.net/ark:/76951/jhcs3h8pa9>

## Copyright

© 2017 KK Quilat, et al.

A diagnosis of Sturge-Weber Syndrome (SWS) is made when two out of three criteria—facial port-wine birthmark, increased ocular pressure, and leptomeningeal angiomas—are present.<sup>1</sup> The facial lesion is a hamartoma that arises from vascular tissue, producing the characteristic port-wine hemangioma of the skin along the trigeminal nerve distribution.<sup>2,3</sup>

Glaucoma occurs in up to 70% of patients with SWS and is usually diagnosed during infancy, but it can develop later during adolescence or adulthood.<sup>1</sup> For late-onset glaucoma, the initial management consists of topical aqueous suppressants and miotics. If topical medications fail, trabeculectomy is the procedure of choice. A cyclodestructive procedure targeting the secretory epithelium of the ciliary body may be performed on eyes with failed medical and surgical interventions.<sup>4</sup>

A 29-year-old man came to our clinic due to eye pain and redness of four years' duration, associated with occasional episodes of headache. There were no accompanying seizures or other neurological symptoms reported. Physical examination revealed a left-sided, flat, well-defined violaceous red patch within the dermatome distribution of the ophthalmic branch of the trigeminal nerve, with irregular borders extending from the left upper eyelid inferiorly to the hairline above the frontal area superiorly, and from one centimeter medial to the left inner canthus medially to the left outer canthus laterally (port-wine stain; Figure 1A). The patient had visual acuity of 20/20 on both eyes.

We found more significant findings on the left eye. Intraocular pressure was 30 mmHg. Slit lamp biomicroscopy revealed dilated and tortuous perilimbal vessels (Figure 1B). Gonioscopic examination revealed open anterior chamber angles on all quadrants. On funduscopy, the optic nerve had a cup-to-disc ratio of 0.7 (Figure 1C). Retinal vessels were noted to be dilated and tortuous. The rest of the ophthalmologic findings were unremarkable. The patient, having port-wine stain and glaucoma, was diagnosed to have Sturge-Weber syndrome.

The patient was initially given timolol eyedrops to control the intraocular pressure (IOP). However, IOP ranged from 24–30 mmHg over a 1-month period. Automated perimetry revealed a temporal quadrantanopsia on the left eye. Both the increase in cup-to-disc ratio and temporal quadrantanopsia were highly suggestive of progressing optic nerve damage and visual field defect on the affected eye.

The patient underwent trabeculectomy on the left eye. On the first postoperative day, the IOP went down to 13 mmHg, the conjunctival bleb was formed and located superonasally, the anterior chamber was shallow, and visual acuity was 20/100. Two weeks after trabeculectomy, the anterior chamber deepened and visual acuity returned to 20/20. A repeat automated perimetry after trabeculectomy revealed no progression of the scotoma (Figure 1D).

## Acknowledgments

We would like to thank Mr Rodel Roño for taking the patient's photo, Dr Elisa Rae Co and Dr Joanne Kate Martinez of the Department of Dermatology in Southern Philippines Medical Center for helping us write the specific description of the patient's physical examination findings, and Dr Luisito Gahol Jr for helping us in the surgical planning for the patient.

## Patient consent

Obtained

## Article source

Submitted

## Peer review

External

## Competing interests

None declared

## Access and license

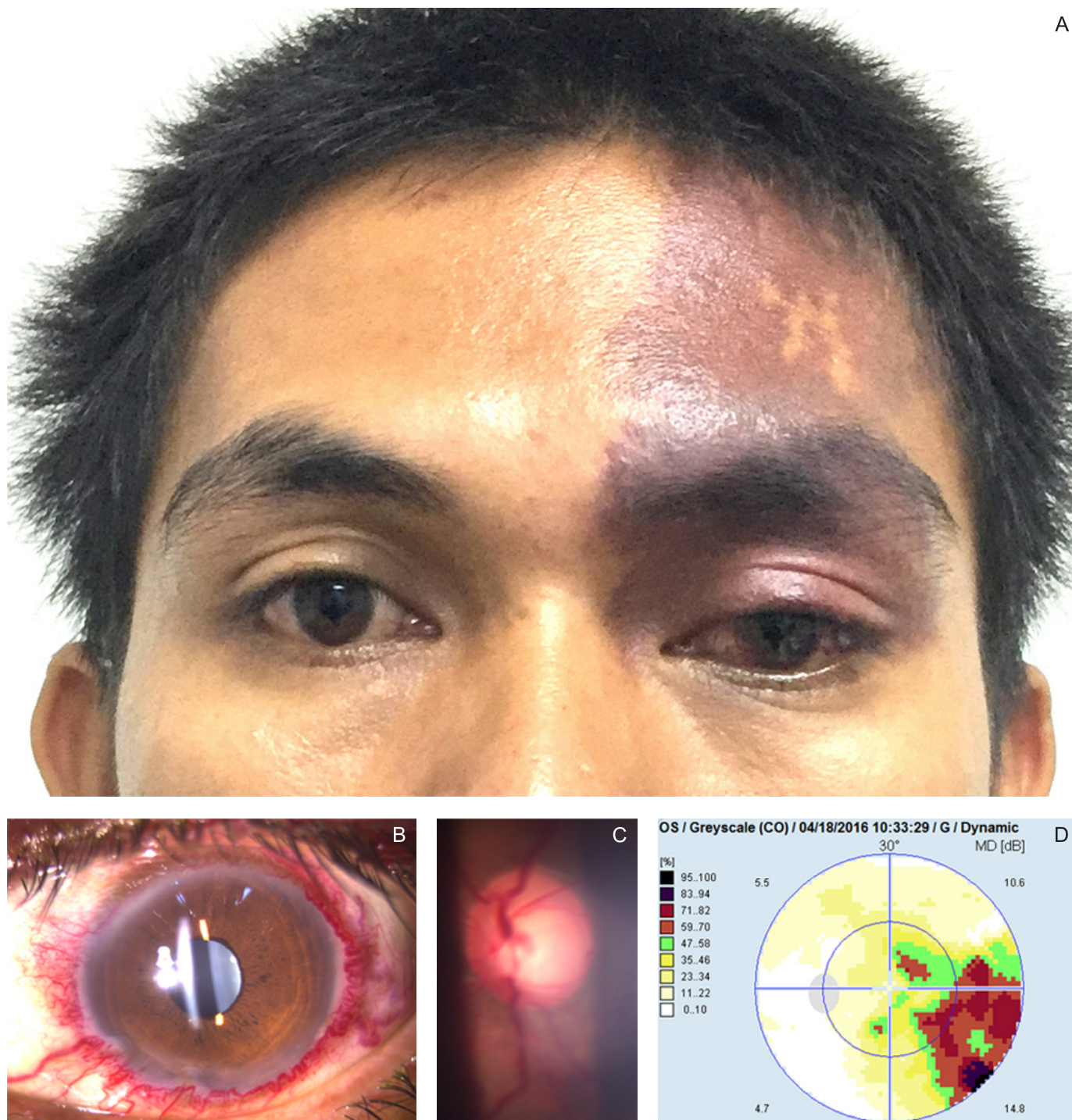
This is an Open Access article licensed under the Creative

Commons Attribution-NonCommercial 4.0 International License, which allows others to share and adapt the work, provided that derivative works bear appropriate citation to this original work and are not used for commercial purposes. To view a copy of this license, visit <http://creativecommons.org/licenses/by-nc/4.0/>

## REFERENCES

1. Bachur CD, Comi AM. Sturge-Weber Syndrome. *Curr Treat Options Neurol.* 2013;15(5):607–17.
2. Akhter K, Salim S. Ophthalmic pearls: Sturge-Weber syndrome and secondary glaucoma. *American Academy of Ophthalmology.* 2014 October.
3. Hampton Roy F, Fraunfelder F, Fraunfelder F. Roy and Fraunfelder's Current Ocular Therapy. 6th ed. Amsterdam: Elsevier; 2007.
4. Mastropasqua R, Fasanella V, Mastropasqua A, Ciancaglini M, Agnifili L. High-Intensity focused ultrasound circular cyclocoagulation in glaucoma: a step forward for cyclodestruction? *J Ophthalmol.* 2017. 2017:7136275.





**Figure 1** Flat, well-defined, violaceous red patch with irregular borders (port-wine stain) on the left frontal area (A). Dilated and tortuous periorbital vessels in the left conjunctiva (B). Cup-to-disc ratio of 0.7 and tortuous and dilated vessels on funduscopy of the left eye (C). Report of automated perimetry test showing left temporal quadrantanopia (D).

#### Southern Philippines Medical Center Journal of Health Care Services Editors

**Editor in chief:** Alvin S Concha • **Issue Editors:** Jesse Jay Baula, Danilo Legita • **Associate Editors:** Seurinane Sean B Española, Aura Rhea D Lanaban, Eugene Lee L Barinaga  
**Managing Editor:** Clarence Xlasi D Ladrero • **Assistant Editors:** Jaryll Gerard Ampog, Rodel C Roño • **Layout Editors:** Jaryll Gerard L Ampog, Rodel C Roño, Clarence Xlasi D Ladrero

**SPMC JHCS OFFICE** Hospital Research Office, Level 1 Outpatient Building, Southern Philippines Medical Center, JP Laurel Avenue, Davao City, Philippines  
**Landline** (+6382) 2272731 loc 4615 • **Website** <http://spmcpapers.com> • **Email** [info@spmcpapers.com](mailto:info@spmcpapers.com)